

Prostate Cancer Staging

7th EDITION

T4

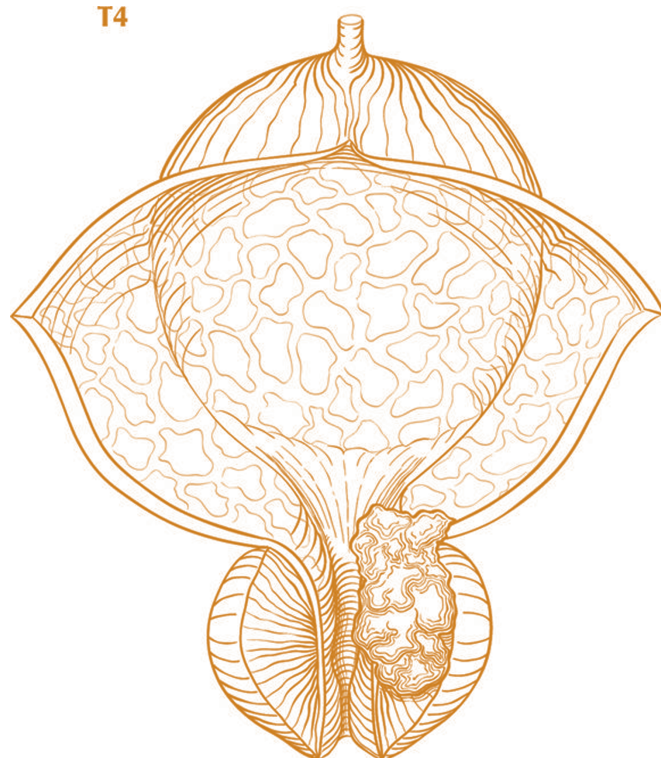


Figure A. T4 tumor invading adjacent structures other than seminal vesicles, such as bladder, rectum, levator muscles, and/or pelvic wall.

ANATOMIC STAGE/PROGNOSTIC GROUPS ⁶					
Group	T	N	M	PSA	Gleason
I	T1a–c	NO	M0	PSA <10	Gleason ≤6
	T2a	NO	M0	PSA <10	Gleason ≤6
	T1–2a	NO	M0	PSA X	Gleason X
IIA	T1a–c	NO	M0	PSA <20	Gleason 7
	T1a–c	NO	M0	PSA ≥10<20	Gleason ≤6
	T2a	NO	M0	PSA ≥10<20	Gleason ≤6
	T2a	NO	M0	PSA <20	Gleason 7
	T2b	NO	M0	PSA <20	Gleason ≤7
	T2b	NO	M0	PSA X	Gleason X
IIB	T2c	NO	M0	Any PSA	Any Gleason
	T1–2	NO	M0	PSA ≥20	Any Gleason
	T1–2	NO	M0	Any PSA	Gleason ≥8
III	T3a–b	NO	M0	Any PSA	Any Gleason
IV	T4	NO	M0	Any PSA	Any Gleason
	Any T	N1	M0	Any PSA	Any Gleason
	Any T	Any N	M1	Any PSA	Any Gleason

Definitions

Primary Tumor (T)

CLINICAL

- TX** Primary tumor cannot be assessed
- T0** No evidence of primary tumor
- T1** Clinically inapparent tumor neither palpable nor visible by imaging
- T1a** Tumor incidental histologic finding in 5% or less of tissue resected
- T1b** Tumor incidental histologic finding in more than 5% of tissue resected
- T1c** Tumor identified by needle biopsy (for example, because of elevated PSA)
- T2** Tumor confined within prostate¹
- T2a** Tumor involves one-half of one lobe or less
- T2b** Tumor involves more than one-half of one lobe but not both lobes
- T2c** Tumor involves both lobes
- T3** Tumor extends through the prostate capsule²
- T3a** Extracapsular extension (unilateral or bilateral)
- T3b** Tumor invades seminal vesicle(s)
- T4** Tumor is fixed or invades adjacent structures other than seminal vesicles, such as external sphincter, rectum, bladder, levator muscles, and/or pelvic wall (Figure A)

Pathologic (pT)³

- pT2** Organ confined
- pT2a** Unilateral, one-half of one side or less
- pT2b** Unilateral, involving more than one-half of side but not both sides
- pT2c** Bilateral disease
- pT3** Extraprostatic extension
- pT3a** Extraprostatic extension or microscopic invasion of bladder neck⁴
- pT3b** Seminal vesicle invasion
- pT4** Invasion of rectum, levator muscles, and/or pelvic wall

Regional Lymph Nodes (N)

CLINICAL

- NX** Regional lymph nodes were not assessed
- N0** No regional lymph node metastasis
- N1** Metastasis in regional lymph node(s)

PATHOLOGIC

- pNX** Regional nodes not sampled
- pN0** No positive regional nodes
- pN1** Metastases in regional node(s)

Distant Metastasis (M)⁵

- M0** No distant metastasis
- M1** Distant metastasis
- M1a** Nonregional lymph node(s)
- M1b** Bone(s)
- M1c** Other site(s) with or without bone disease

Notes

- ¹ Tumor found in one or both lobes by needle biopsy, but not palpable or reliably visible by imaging, is classified as T1c.
- ² Invasion into the prostatic apex or into (but not beyond) the prostatic capsule is classified not as T3 but as T2.
- ³ There is no pathologic T1 classification.
- ⁴ Positive surgical margin should be indicated by an R1 descriptor (residual microscopic disease).
- ⁵ When more than one site of metastasis is present, the most advanced category is used. pM1c is most advanced.
- ⁶ When either PSA or Gleason is not available, grouping should be determined by T stage and/or either PSA or Gleason as available.



Financial support for AJCC 7th Edition Staging Posters provided by the American Cancer Society

